

Morphometric Sex Identification Based on Paranasal Sinus Dimensions in the Indian Population: A CBCT Based Study

JIJIN MEKKADATH JAYAKRISHNAN¹, JAGAT REDDY², RB VINOD KUMAR³



ABSTRACT

Introduction: The creation of technologies using anatomical components like the maxillary sinus and frontal sinus that might preserve their stability yet after extreme events, are helpful for forensic investigations because sex determination is a crucial component of determining the profile of an individual.

Aim: To determine the sex using Cone Beam Computed Tomography (CBCT) scans, in a South Indian community by measuring the frontal and maxillary sinuses.

Materials and Methods: The present cross-sectional study was conducted in the Department of Oral Medicine and Radiology, Sri Balaji Vidyapeeth University, IGIDS, Puducherry, India, from 1st March 2021 to 31st March 2022. Analysis included 45 CBCT scans from 22 males and 23 females were subjected to volumetric measures in the maxillary sinus and frontal sinus. Applying NNT software, the volume measurement was carried out. The data

was used to feed into a sex identification mathematical model. For evaluation, the student's t-test has been used.

Results: In the total study subjects, the mean age of males was 36.909 years and of females was 36.304 years. Only the volume of the frontal sinus varied significantly among males and females (p-value <0.001). The discriminant function analysis equation showed that 50% of males and 91.3% of females correctly identified their gender. According to the cross-validated categorisation, 71.1% of the people were accurately categorised altogether.

Conclusion: Segregation identification, which was validated with evaluations in the frontal and maxillary sinuses with CBCT scans, is another technique for identifying individuals who identify as Indian. The present study shows that paranasal sinus morphologic evaluation is a useful method for identifying a person's gender.

Keywords: Cone beam computed tomography, Forensic anthropology, Forensic dentistry, Frontal sinus, Maxillary sinus

INTRODUCTION

Forensic odontology has evolved alongside technological and data capture approaches throughout the growth of civilisation [1]. Forensic odontology has gained recognition as a crucial discipline in medicolegal cases and the authentication of the deceased over time. In order to evaluate and examine injuries to the jaws, oral tissues, and teeth brought on by a variety of events, to recognise or rule out a suspect as a predator by examining bite marks, and eventually to examine fragments or complete dental remains in order to potentially identify an individual particularly in situations involving large-scale disasters, forensic odontology expertise is being used [2].

The skull can be the sole section of the skeleton that is still accessible for forensic analysis because it is the portion of the human body that is most frequently preserved after life. The amount of criminal cases has increased recently, particularly those involving murder and body burning. In cases where facial features are fully distorted, then identification of the deceased possesses a challenge to the forensic experts. In such cases, the identification is established based on possible age, gender, race, stature, any injury marks, certain distinctive features including polydactyly, callus of old fracture or the presence of an extra rib. Even though these features are useful in identifying a deceased, they may not be completely successful in identification based on a human skull [3].

Determining a person's gender is vital in medicolegal proceedings, particularly when the body is fractured and degraded, as in natural calamities, large-scale tragedies, or crime scenes. Some of the bodily parts utilised in sexual identity include the skull, pelvis, long bones, foramen magnum, sella turcica, mandibular ramus and paranasal sinuses. Unfortunately, it can be difficult to determine the gender of these bones because they are frequently found either fractured or fragmentary. Because they are frequently retrieved whole, denser bones like the maxilla can be used [4].

Males and females in diverse populations have varied maxillary sinuses in terms of shape and dimensions, according to evidence from numerous research [4-6]. When teeth are lost in maturity, the maxillary sinus may grow or shrink in size. Also, all genders experience a decrease in maxillary sinus size following the peak of their development because of the depletion of nutrients in the bone [4]. The frontal sinus is yet another craniometric characteristic of significance in forensic identification owing to its uneven form [7]. A study examining the relationship between the frontal sinus and gender found that females have smaller frontal sinuses than males [8]. In forensic odontology, radiography has been employed, particularly when the body is charred, degraded, or shattered [9]. Radiographic examinations are frequently used to determine age, gender, the location of gunshots and the wound tracks they left behind, and to evaluate the fragmentary remnants of the skull as well as other body parts. Computed Tomography (CT), which can show anatomical structures in three dimensions, has proven use in less invasive postmortem procedures like virtopsies [10,11]. The imaging technique of the next generation, CBCT, has a number of functional and technological advantages over traditional CT. CBCT images have less metallic artefacts than CT images. Moreover, CBCT image reconstruction is quicker and reduces radiation exposure by 96% compared to traditional CT [12]. CBCT has been shown to be useful in determining gender using a variety of anatomical features in numerous investigations [13-15].

In the current study authors identified gender, based on measures of the frontal and maxillary sinuses taken using CBCT images. This study's main aim was to identify the sex using paranasal sinus measures from CBCT pictures. Before proceeding with the volumetric analysis of the paranasal sinuses using New Net Technologies (NNT) software, authors did the present pilot study to determine the feasibility of the study.

MATERIALS AND METHODS

The present cross-sectional study was conducted in the Department of Oral Medicine and Radiology, Sri Balaji Vidyapeeth University, IGIDS, Puducherry, India, from 1st March, 2021 to 31st March 2022. This research examined CBCT scans of 45 patients gathered from all over India. The ethical approval was obtained from Institutional Ethical Committee (IECSHST-03/MDC/2020). A convenient sample of 45 patients was considered. Images from different centres were procured. This study included a mixed cohort of North and south Indian population.

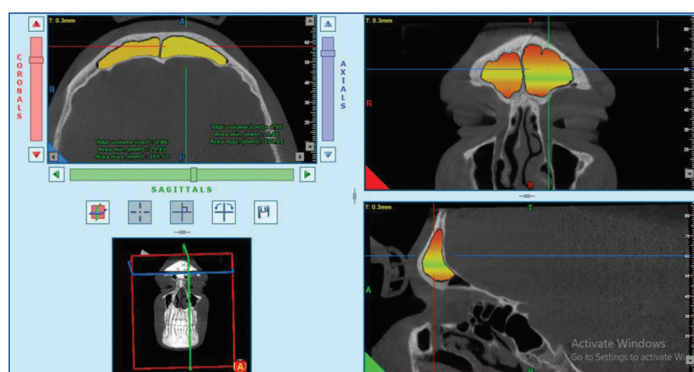
Inclusion criteria: CBCT scans of people above the age of 18 years, who were recommended for a head and neck CBCT examination, with both the maxillary and frontal sinuses fully visible in the pictures were included in the study.

Exclusion criteria: CBCT images having deformed or artifactual images, scans showing symptoms of sinus diseases and imaging with surgical defects were excluded from the study.

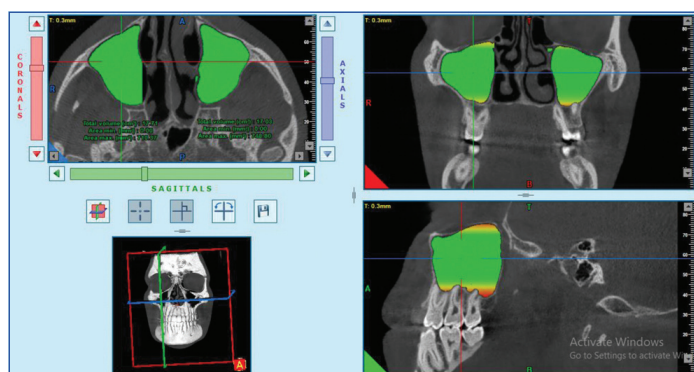
Study Procedure

The scan settings for the images (axial and coronal images) were 90 kV (peak), 6 mAs, and matrix size of 16#18 fov on a Newton Machine CBCT scanner with New Net Technologies (NNT) software. The homogeneity of all the characteristics related to CBCT scanning was maintained while choosing the CBCT images for the investigation. Based on the predetermined selection and exclusion criteria, a radiologist with expertise in CBCT image analysis chose the research images.

All study participants had their frontal sinuses and right and left maxilla volumetric measurements obtained. Radiologists with past knowledge analysing CBCT pictures and education in the NMT programme carried out all of the assessments [Table/Fig-1,2].



[Table/Fig-1]: CBCT scans of frontal sinus.



[Table/Fig-2]: CBCT scans of maxillary sinus.

STATISTICAL ANALYSIS

The obtained data were presented using descriptive analysis using the mean, standard deviation, and percentage values. The student's t-test was used to compare the two groups based on sex, with a p-value of 0.05 being considered significant. The next step was doing a discriminant functional analysis to determine the sex

according to the findings of measures of the frontal and maxillary sinus dimensions. SPSS software version 15.0 was used for the data analysis.

RESULTS

Out of total 45 participants enrolled in the trial, 23 were females and 22 were males with a mean age of 36.909 years and 36.304 years in males and females, respectively. The mean, standard deviation, and p-value of each predictor value for both men and women are shown in [Table/Fig-3]. The volume of the frontal sinus differed significantly between boys and females based on the student's t-test (p-value <0.001) [Table/Fig-3].

Sinus	Gender	n	Mean	Standard deviation	Standard error mean	F	p-value
Maxillary sinus	Females	23	14.3435	3.77501	0.78714	3.957	0.053
	Males	22	23.2145	20.19772	4.30617		
Frontal sinus	Females	23	2.2087	1.03143	0.21507	17.787	<0.001
	Males	22	4.9432	3.44784	0.73508		

[Table/Fig-3]: Descriptive analysis of volume of the sinuses in males and females. The p-value in bold font indicates statistically significant values

Discriminant function was calculated using the formula, Discriminant function=-1.289-0.021 (Maxillary sinus)+0.473 (Frontal sinus). A cut-off value of 0.025 was obtained for the formula used. The score above the cut-off was to be classified as males and below the cut-off as females.

Based on discriminant function analysis, gender assessment was achieved accurately in 50% males and 91.3% females. The overall classification accuracy was 71.1%, according to the cross-validated classification [Table/Fig-4].

Gender	Predicted group membership		Total, n (%)
	Females, n (%)	Males, n (%)	
Females	21 (91.3)	2 (8.7)	23 (100)
Males	11 (50)	11 (50)	22 (100)

[Table/Fig-4]: Accuracy of prediction based on discriminant functional analysis. 71.1% of original grouped cases correctly classified

DISCUSSION

Sexual dimorphism is an important part of forensic sciences for the accurate identification of the deceased individual. Evidence from literature has reported the anatomic variations of maxillary sinus among males and females [16,17]. The maxillary sinus dimensions among males and females in the current study differed significantly. According to a study by Kim HJ et al., using 33 hemisectioned reconstructed CT images of the maxillary sinus in the Korean population, men had a larger maxillary sinus than women do in terms of anteroposterior length, height, width and volume of the sinus [18]. In a similar manner, Tambawala SS et al., study revealed that males had considerably higher maxillary sinus total values than females did, with the strongest indicators of sexual dimorphism having right height (90.0%) and left height (83.3%) [17].

The frontal sinus, which is particular to every person, is another significant paranasal sinus that is examined for sexual dimorphism. In investigation process, the frontal sinus is considered because it is a constant anatomical site across human existence [15]. The frontal sinus also has an arched morphometry and an internal skeletal structure, which accounts for its full preservation in skeletal bones [19,20].

In the present investigation, males frontal sinuses were noticeably bigger than females. The present study findings are consistent with those made public by Soman BA et al., and Shireen A et al., [21,22]. In contrast to what was shown in the investigation, Soman BA et

al., study found a substantial difference seen between genders, with males having larger frontal sinuses than females [21]. Shireen A et al., study found that the Saudi population's morphology varied significantly by age and gender [22]. The majority of investigations on sexual dimorphism have been carried out utilising CT scan images and regular plain images, despite the fact that the majority of previous research have found higher frontal and maxillary sinus measurements in males. The present work was unique, since authors used CBCT pictures to ensure a 1:1 depiction of the images with no amplification and less metallic artefacts.

Limitation(s)

The limited sample size of this study is one of its weaknesses, which highlights the need to carry out these studies on a wider population. Secondly, authors used CBCT scans for assessing gender and CBCT machines are available only in major cities of India and hence there is limited access to the general population. Further, there might be interpopulation variations affecting morphological features of the sinuses. As a result, the results need to be read carefully. The findings of the present investigation demonstrate the reliability and precision of employing a limited set of morphological traits to identify unknown skeletal remains and to ascertain the sex.

CONCLUSION(S)

The paranasal sinus morphologic evaluation is a useful method for identifying a person's gender. An excellent way to image the maxillofacial areas is with CBCT. Authors conclude that gender dimorphism can be detected using the maxillary and frontal sinus dimensions from the findings of the current investigation.

REFERENCES

- Balachander N, Babu NA, Jimson S, Priyadharsini C, Masthan KMK. Evolution of forensic odontology: An overview. *J Pharm Bioallied Sci.* 2015;7(Suppl 1):S176-80. Doi: 10.4103/0975-7406.155894.
- Jeddy N, Ravi S, Radhika T. Current trends in forensic odontology. *J Forensic Dent Sci.* 2017;9(3):115-19. Doi: 10.4103/jfo.jfds_85_16.
- Sahni D, Sanjeev Null, Singh G, Jit I, Singh P. Facial soft tissue thickness in northwest Indian adults. *Forensic Sci Int.* 2008;176(2-3):137-46. Doi: 10.1016/j.forsciint.2007.07.012.
- Bangi BB, Ginjupally U, Nadendla LK, Vadla B. 3D Evaluation of maxillary sinus using computed tomography: A sexual dimorphic study. *Int J Dent.* 2017;2017:9017078. Doi: 10.1155/2017/9017078.
- Kanthen RK, Guttikonda VR, Yeluri S, Kumari G. Sex determination using maxillary sinus. *J Forensic Dent Sci.* 2015;7(2):163-67. Doi: 10.4103/0975-1475.154595.
- Prabhat M, Rai S, Kaur M, Prabhat K, Bhatnagar P, Panjwani S. Computed tomography based forensic gender determination by measuring the size and volume of the maxillary sinuses. *J Forensic Dent Sci.* 2016;8(1):40-46. Doi: 10.4103/0975-1475.176950.
- Choi IGG, Duailibi-Neto EF, Beaini TL, da Silva RLB, Chilvarquer I. The frontal sinus cavity exhibits sexual dimorphism in 3D cone-beam CT images and can be used for sex determination. *J Forensic Sci.* 2018;63(3):692-98. Doi: 10.1111/1556-4029.13601.
- Tatlisumak E, Asircizer M, Bora A, Hekimoglu Y, Eti Y, Gumus O, et al. The effects of gender and age on forensic personal identification from frontal sinus in a Turkish population. *Saudi Med J.* 2017;38(1):41-47. Doi: 10.15537/smj.2017.1.16218.
- Brogdon BG. The scope of forensic radiology. *Clin Lab Med.* 1998;18(2):203-40. Doi: 10.1201/9781420048339.ch3.
- Ruder TD, Kraehenbuehl M, Gotsmy WF, Mathier S, Ebert LC, Thali MJ, et al. Radiologic identification of disaster victims: A simple and reliable method using CT of the paranasal sinuses. *Eur J Radiol.* 2012;81(2):e132-38. Doi: 10.1016/j.ejrad.2011.01.060.
- Thali MJ, Yen K, Vock P, Ozdoba C, Kneubuehl BP, Sonnenschein M, et al. Image-guided virtual autopsy findings of gunshot victims performed with multi-slice computed tomography (MSCT) and magnetic resonance imaging (MRI) and subsequent correlation between radiology and autopsy findings. *Forensic Sci Int.* 2003;138(1-3):08-16. Doi: 10.1016/S0379-0738(03)00225.
- Issrani R, Prabhu N, Sghaireen MG, Ganji KK, Alqahtani AMA, ALJamaan TS, et al. Cone-beam computed tomography: A new tool on the horizon for forensic dentistry. *Int J Environ Res Public Health.* 2022;19(9):5352. Doi: 10.3390/ijerph19095352.
- Okkesim A, Sezen Erhamza T. Assessment of mandibular ramus for sex determination: Retrospective study. *J Oral Biol Craniofac Res.* 2020;10(4):569-72. Doi: 10.1016/j.jobcr.2020.07.019.
- Urooge A, Patil BA. Sexual dimorphism of maxillary sinus: A morphometric analysis using cone beam computed tomography. *J Clin Diagn Res.* 2017;11(3):67-70. Doi: 10.7860/JCDR/2017/25159.9584.
- Patil N, Karjodkar FR, Sontakke S, Sansare K, Salvi R. Uniqueness of radiographic patterns of the frontal sinus for personal identification. *Imaging Sci Dent.* 2012;42(4):213-17. Doi: 10.5624/isd.2012.42.4.213.
- Sathawane SR, Sukhadeve AV, Chandak MR. Sex determination by maxillary sinus dimensions using cone-beam computed tomography and discriminant function: An analytical study. *Int J Forensic Odontol.* 2020;5(1):19-22.
- Tambawala SS, Karjodkar FR, Sansare K, Prakash N. Sexual dimorphism of maxillary sinus using cone beam computed tomography. *Egypt Journal of Forensic Sciences.* 2016;6(2):120-25.
- Kim HJ, Yoon HR, Kim KD, Kang MK, Kwak HH, Park HD, et al. Personal-computer-based three-dimensional reconstruction and simulation of maxillary sinus. *Surg Radiol Anat.* 2003;24(6):393-99.
- Marlin DC, Clark MA, Standish SM. Identification of human remains by comparison of frontal sinus radiographs: A series of four cases. *J Forensic Sci.* 1991;36(6):1765-72.
- Nambiar P, Naidu MD, Subramaniam K. Anatomical variability of the frontal sinuses and their application in forensic identification. *Clin Anat.* 1999;12(1):16-19.
- Soman BA, Sujatha GP, Lingappa A. Morphometric evaluation of the frontal sinus in relation to age and gender in subjects residing in Davangere, Karnataka. *J Forensic Dent Sci.* 2016;8(1):57.
- Shireen A, Goel S, Ahmed IM, Sabeh AM, Mahmoud W. Radiomorphometric evaluation of the frontal sinus in relation to age and gender in Saudi population. *J Int Soc Prevent Communit Dent.* 2019;9(6):584-96.

PARTICULARS OF CONTRIBUTORS:

- PhD Scholar, Department of Oral Medicine and Radiology, Sri Balaji Vidyapeeth University, IGIDS, Puducherry, India.
- Professor and Head, Department of Oral Medicine and Radiology, Sri Balaji Vidyapeeth University, IGIDS, Puducherry, India.
- Principal, Department of Oral Pathology and Microbiology, PSMDC, Thrissur, Kerala, India.

NAME, ADDRESS, E-MAIL ID OF THE CORRESPONDING AUTHOR:

Dr. Jijin Mekkadath Jayakrishnan,
PhD Scholar, Department of Oral Medicine and Radiology,
Sri Balaji Vidyapeeth University, Puducherry, India.
E-mail: drjijin@gmail.com

PLAGIARISM CHECKING METHODS: [\[Jain H et al.\]](#)

- Plagiarism X-checker: Nov 25, 2022
- Manual Googling: Mar 10, 2023
- iThenticate Software: Mar 13, 2023 (2%)

ETYMOLOGY: Author Origin

AUTHOR DECLARATION:

- Financial or Other Competing Interests: None
- Was Ethics Committee Approval obtained for this study? Yes
- Was informed consent obtained from the subjects involved in the study? Yes
- For any images presented appropriate consent has been obtained from the subjects. Yes

Date of Submission: **Nov 22, 2022**

Date of Peer Review: **Dec 28, 2022**

Date of Acceptance: **Mar 14, 2023**

Date of Publishing: **Jun 01, 2023**